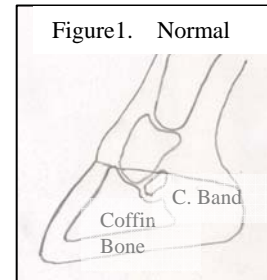


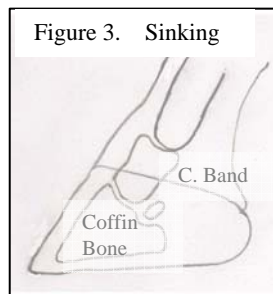
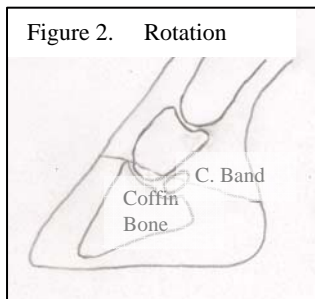
# Laminitis

Judy Marteniuk, DVM  
Michigan State University

Laminitis is the last article in the series on “How does your donkey score?”. Laminitis, often called founder, is an inflammation in the lamina in the foot. First, a review of anatomy of the equine foot will facilitate a better understanding of laminitis. All equids walk on a single digit. For comparison, our fingernail is equivalent to their hoof capsule and the connection of our fingernail to the deeper tissue is the lamina. During laminitis, the attachment (lamina) of the hoof wall (fingernail) is disrupted from a critical element of the underlying tissue, the coffin bone (Figure1).



Imagine the pain that occurs when your fingernail is torn back into the sensitive tissue or bent back, now imagine having to bear all your weight and walk on that fingernail. This gives you an idea of the pain involved with the acute form of the disease. Typically, only the front feet are involved, but in severe cases all four feet may be involved. During the acute (active) stage of laminitis, the individual feet are extremely painful. Depending upon the severity of the inflammation, the pain may be short-lived without obvious changes in the foot; or so severe that the coffin bone alters its position within the hoof capsule. Two types of movement are possible. The one type that most people are aware of is “rotation of the coffin” within the hoof capsule (Figure 2). With rotation only, the lamina at the toe is disrupted. The other type is the breakdown of entire laminar connection between the coffin bone and the hoof wall that leads to the coffin bone sinking within the hoof capsule (Figure 3). If this form is severe enough, the hoof capsule may be left behind, ie the coffin bone comes out of the hoof capsule- just like stepping out of a shoe.



The severity of the disease and the commitment of the owner will determine the outcome, with euthanasia one of the scenarios. Studies reviewing long-term outcomes of laminitis in horses, report that 75% of those affected were euthanized. Since donkeys seem to be much more pain tolerant than horses, are not usually “athletes” and are more inclined to keep off their feet during the acute aspect of the inflammation, they seem to have a better outcome for long-term survival.

The form of laminitis most commonly seen by the Rescue is the chronic form. When the lamina of the foot is damaged by inflammation, hoof growth often changes. The heels grow faster than the toe, leading to the characteristic “elf slipped” appearance of the foot. In the absence of routine, regularly scheduled farriery, the hoof walls of affected donkeys may actually curl. As can be imagined, the donkeys become very painful on their feet and are very reluctant to walk. Also, due to inflammation, the white line area of the hoof is damaged, and becomes quite wide and spongy in consistency. This is most prevalent at the toe for those suffering rotation. White line damage can lead to an increased incidence of “gravel” or hoof abscesses involving the white line.

Treatment of laminitis involves removing/correcting the inciting cause, pain control and regular hoof care. If your donkey has foundered due to being overweight, then dietary changes are necessary. Other causes of laminitis include sudden feed changes, especially eating too much concentrate/grain; severe illness, especially if the intestinal tract is involved; and injuries to the opposite leg that require more weight to be placed on the supporting leg. Adequate pain control may be very difficult to achieve in severe cases. The simultaneous use of several methods is often necessary. Medications, such as phenylbutazone (Bute) and Banamine, are the most commonly used for pain control. These medications are non-steroidal anti-inflammatory drugs (NSAID's) and are in the same group of drugs as aspirin and ibuprofen. It is important to remember that these drugs can have severe and even life-threatening side effects if not used correctly. Other pain medications, such as detomidine, may also be used. In addition during the acute phase of the disease, it is important to keep the donkey confined to a stall or very small paddock, whether it is a new occurrence or a flare-up of chronic disease. This, along with a soft, well-bedded surface, will help relieve

pain by providing both support to the foot and encouraging the donkey to lie down and take weight off its feet. Stall confinement may be necessary for only a few days or may be required for months. It takes about a year for a hoof to re-grow fully. Finally, it is essential to have a close working relationship with a farrier who is experienced both in trimming donkey feet and dealing with laminitis. In contrast to the goal of routine trimming of horses' hooves, donkeys are meant to have a normal more upright hoof wall. More heel should be left on a properly trimmed donkey hoof. This correct, more upright stance and trim becomes even more critical for donkeys affected by laminitis. A donkey-knowledgeable farrier or veterinarian may also elect to place pads on the hooves to provide extra sole support. Therefore, if faced with a severe case of laminitis in your donkey, a successful outcome will be greatly enhanced by a strong working relationship between you, your veterinarian and your farrier, coupled with your willingness and dedication to follow their directions for care.

In closing, if your donkey founders, it is going to be a potentially long, involved, expensive, and most importantly, an emotionally draining experience. It is extremely difficult to watch your donkey in pain during the healing process. Prevention of laminitis is preferable, but treatment should be considered and may be rewarded.

\*\*\*\*\*