

Anatomical Differences of the Donkey and Mule

Suzanne L. Burnham, DVM

Author's address: Burnham Veterinary Hospital, Inc., Graham, TX 76450. © 2002 AAEP.

1. Introduction

The donkey is not just a smaller, inferior type of horse. To those who have taken the time to get to know him, the donkey is a unique equine of special qualities. Yet he is an evolutionary relative of the horse and so will forever be compared with the horse. The mule, however, is still a scientific enigma.

The mule has been described as the animal without "pride of ancestry, nor hope of posterity" or, by the muleskinners, as "900 lbs of free enterprise" (Fig. 1).

Very little of what is known about the mule comes from scientific research. Folklore and muleskinners teach us that a mule is a creature of habit; that mules enjoy a good roll at the end of the day's work, and that mules recover from a hard day's work faster than a horse. Muleskinners were men who understood mule behavior and learned to work around their peculiarities without injury. Although their knowledge of mules may not be based on scientific research, we can still benefit from their wisdom. Veterinarians that work around mules need to be wary because mules are very agile; a mule can strike with any other hoof even if a man is holding one up. Veterinarians need to be patient and work quietly and gently around a mule, but they need to work with purpose and conviction. For the veterinarian working on mules, it is not only impor-

tant to be a good horseman but also to know the ways of a good muleskinner.

Because mules vary so much in genetic makeup, they do not make good subjects for research; therefore, for scientific data, we rely on studies of the donkey. What do we know about donkeys and how do they differ from horses? A donkey brays and has long ears, but those are not the only differences. He has a completely different outlook on life, drinks water differently, reacts to frightening situations differently, has very different nutrient requirements, and has unique physiological responses. Many common rules of horse management are detrimental to the donkey. For instance, the normal ration for a horse will make a donkey obese, possibly cause him to founder, and may result in decreased fertility. The horse dosage interval of penicillin does not produce therapeutic blood levels in the donkey. Castrating the donkey or mule by the routine method used in horses, without ligation, may result in such excessive bleeding, and some have died as a result (Fig. 2).

It is the purpose of this session, therefore, to demonstrate ways that donkeys and mules differ from horses as far as we know it at this time.

Donkeys and mules are exceptionally revered by their owners, and in recent years, in some parts of the world, their value has increased to equal or

NOTES

IN DEPTH: MULE/DONKEY MEDICINE AND SURGERY



Fig. 1. "... without pride of ancestry, nor hope of posterity."

exceed that of the horse. These owners are looking to you for competent advice.

2. An Interesting Historical Note

In 1785, George Washington investigated the purchase of a good jack from Spain but was told that the exportation of jacks was illegal in Spain. However, when the king of Spain learned that George Washington wanted a good jack to produce work mules in America, he sent a jack and a jennet as a gift. The jack was named "Royal Gift" and stood at Mt. Vernon. "Royal gift" was between 14.2 and 15 H tall and commanded a stud fee that was higher than the



Fig. 2. Donkeys are not just horses with long ears.



Fig. 3. Miniature donkeys are valued for their temperament.

fee for some excellent stallions of his time. The following year, the Marquis de Lafayette sent Washington a Maltese jack named the "Knight of Malta," which was described as "having the fire and ferocity of a tiger," but he was an excellent sire of mules. Thus, George Washington played a major role in the development of the mule industry in America. By 1840, a quality jack used for mule breeding could fetch up to \$5000.00 in Kentucky, then as now, a state that leads in mule production.

3. Donkey Definitions

The *donkey*, or domestic ass, is an equine species consisting of many breeds, just as there are breeds of horses and zebras. It will not be within the scope of this paper to identify all the African Wild ass breeds and world-wide domestic ass breeds. In North America, the donkeys under 36 inches at the withers are identified by the Mediterranean miniature donkey registries and are valued for their temperament (Fig. 3). The breed standard for the miniature identifies them as stocky, sturdy, and willing to work the cart. The larger breed, or mammoth Jackstock, has its own registry and includes the taller, heavier boned donkeys descended from the European donkey breeds that were originally imported primarily for mule production. Mammoth donkeys measure 14 H and over, which makes them very suitable as riding animals. Other donkeys found in North America in the sizes ranging between miniature and mammoth breeds are derived from Spanish breeds, including the dappled grey and white Andalusian, the dun and brown donkeys from Zamora and Catalonia. In the Southwest, people refer to the grey dun feral donkey as a "burro"; a name that is also derived from Spanish. Donkeys of the mid-range size have never attained the

IN DEPTH: MULE/DONKEY MEDICINE AND SURGERY

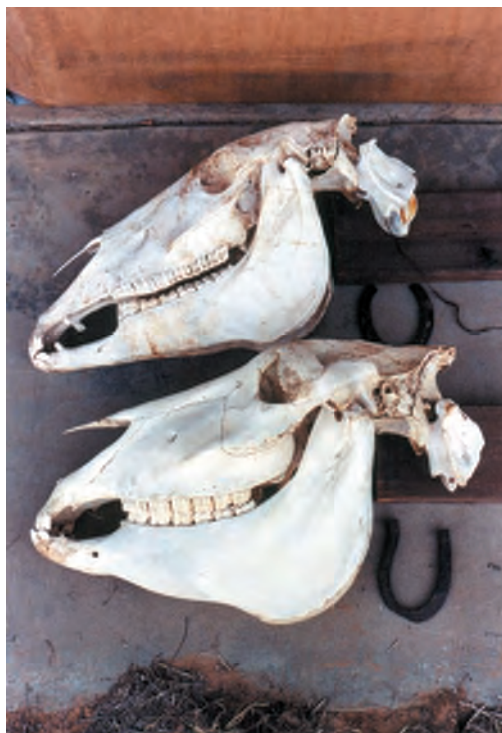

Fig. 4. Both the horse (top) and the donkey (bottom) weighed approximately 450 kg in life. The donkey was a mammoth breed of donkey.

status of the other sizes, yet this size is the work donkey in many countries of the world.

The male donkey is called the *jack*. Jacks are fertile, and like stallions, can be very aggressive when they mature. Young jacks in the wild are ousted from the jenny bands not only for the aggravation they cause the jennies but because they will savage the young. Cattlemen during the era of open grazing would shoot wild jacks on the open range because they were aggressive enough and had jaws strong enough to pick up a young calf and throw him hard enough to kill him. If a jack is to be used for breeding, he should be housed separately; if not, he should be castrated.

The female donkey is called a *jennet* or *jenny*. Jennies are valued for herd protection in many parts of the world because of their aggression to dogs, coyotes, and other predators. There have been reports that jennies protect their own young in groups, forming a circle around the foals and kicking at mountain lions or tigers savagely enough to deter these large cats. A jenny without a foal will make a pleasant companion as a pet but may still show aggression to stray dogs.

By far the most popular donkey pet is the *donkey gelding*. They willingly pull a cart, serve as a mount or pack animal, and give years of uncomplaining service and companionship.

The *mule* is the resulting offspring of the jack donkey bred to a mare. The mares usually determine the type of work the mule will perform. The

quality of the mule can be inherited from both parents. Therefore, the large coarse-boned jacks are not as popular for mule production as the fine-boned jacks. The reciprocal breeding, that is, the jenny donkey bred to a stallion produces what is referred to as a "*hinny*."

4. Donkeys Are Different

A donkey is distinguished from a horse by his longer ears, his short upright mane, and by the coloration on his head: the lighter, finer hair on his muzzle and around his eyes. Donkeys bray and horses nicker. Donkeys have no forelock and have a switch for a tail. (Mules have full tails but many lack the forelock.) The hair in the flank of the donkey has no upward whorl and the donkey has chestnuts only of the front limbs. (Mules will have a half whorl and variable chestnuts.) The ergots of the donkey tend to be more prominent and suggestive of a vestigial footpad. Some male donkeys have teats on their sheath and have proportionately longer reproductive organs than horses. Donkeys have small boxy hooves with thicker hoof walls and a more upright hoof angle. Donkeys have lower withers and more prominent anterior manubria (the sternum protrudes further cranially), and the donkey pelvis is a different shape. The donkey mandible is formed of thicker, more dense, bone, and the space is narrower than that of the horse (Fig. 4).

The diploid chromosome number for the domestic horse is 64, for the domestic ass it is 62, and for the Asiatic wild ass it is 54–56. Gestation for the domestic horse ranges from 335 to 346 days and for the domestic ass it is 365–370 days.

Donkeys are said to have greater longevity than horses, often beyond 45 years. One difficulty in proving this with donkeys is that the eruption schedule of their teeth does not match that of the horse. The schedule is delayed so that a 10-year-old donkey does not yet have a smooth mouth. The other factors used to determine age ranges for horses do not apply to the donkey because they do not have the same shape corner tooth.

5. Differences of Veterinary Significance

Laryngeal Anatomy

The laryngeal anatomy of the donkey was described in the 19th century, and references to the differences in the topography of the larynx and pharynx were primarily noted as an explanation of the bray sounds that the donkey makes. The vocal folds and laryngeal sacculae were identified and found to be different from those of horses and ponies.¹

An in-depth study of the nasopharynx and larynx of the donkey was done by Lindsay and Clayton,² who compiled information from various cross-sectioned donkey heads; the exact size and description of the structures unique to the donkey were documented in detail. Although vocalization in the donkey was included in this study, the structure and

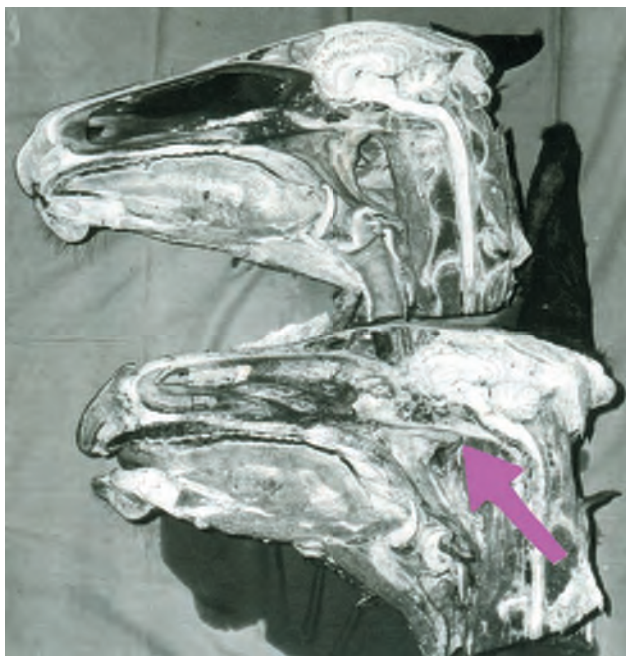

Fig. 5. Arrow indicates the caudal margin of the laryngeal diverticulum of the donkey in this cross-sectioned head. Compare with the horse above.

functional anatomy and the patho-physiology of the respiratory tract of the donkey were the primary goals.

This study documents two important features of the donkey larynx that differ greatly from horses:

1. the presence of an extended recess between the openings of the guttural pouches and
2. the angle of the airway and aditus laryngis that differs from horses (Fig. 5).

Although the process of vocalization in the donkey makes an interesting study, a practical concern with the anatomy of the larynx is for naso-gastric tube placement. The particular structure unique to the donkey, the pharyngeal recess or diverticulum, is located caudo-medially to the guttural pouches (Fig. 6). This pharyngeal recess in the donkey has a slightly constricted opening, is about 2–3 cm in diameter and stretches to 6–7 cm in length.^{2,4} Its central location in the pharynx puts it in a direct line to entrap the nasogastric tube, preventing it from passing through to the esophagus.

Another unique feature of the donkey is the angle of the opening of the airway from the pharynx to the larynx, which tilts on average 5.5° caudally. This differs from the horse, where the aditus angles rostrally 2.5° from the perpendicular.² In a recent study, this angle caused difficulty in visualizing the trachea with an endoscope, but the scope could pass easily directly into the diverticulum.³

One additional difference is that the donkey typically has a narrower ventral meatus than a horse or

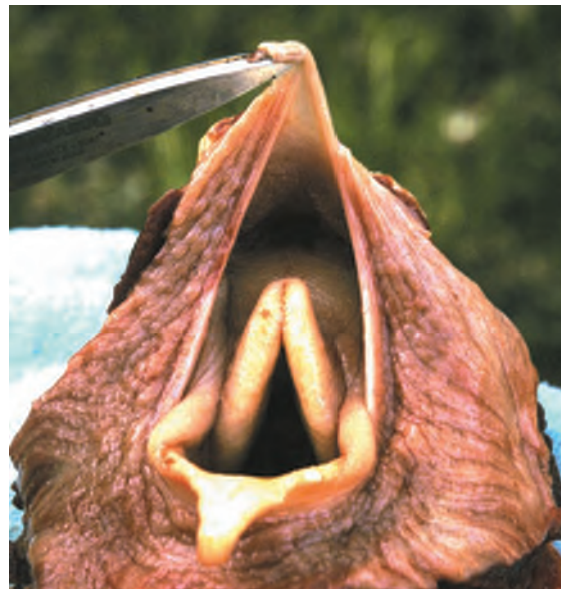

Fig. 6. This fresh specimen of the donkey pharynx shows how the donkey's laryngeal diverticulum could easily entrap a nasogastric tube.

pony of equivalent size and age.³ The donkey has the reputation of excessive bleeding during the procedure of passing the tube. This may be because the nasal passage is so narrow or because the recess traps the tube. The practitioner will have better success entering this very narrow nasal passage by using a small diameter tube.

Cutaneus Colli Muscle

According to the classic anatomy textbook, the horse has a thin myo-fascial layer, called the cutaneus colli muscle, that is peeled away during the dissection process to reveal the jugular furrow. The cu-



Fig. 7. Notice the shape of the neck of this large jack donkey. The jugular furrow is obscured by the cutaneus colli muscle.

IN DEPTH: MULE/DONKEY MEDICINE AND SURGERY

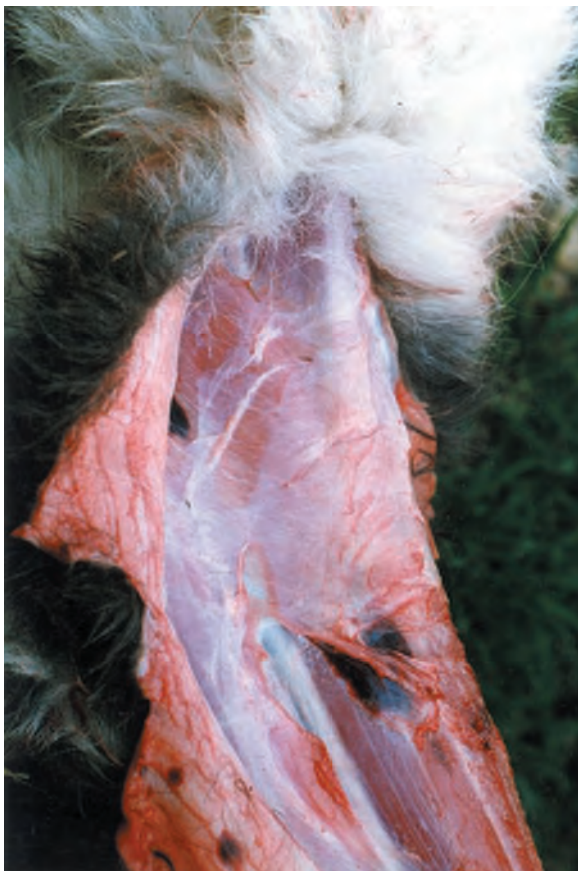

Fig. 8. Two-week-old miniature donkey foal. Even in the immature donkey, the cutaneous colli muscle obscured part of the jugular furrow and the jugular vein. The bruise (center) is the result of a failed attempt at venapuncture.

taneous colli muscle of the horse is a relatively small V-shaped muscle developed in the superficial fascia on the caudoventral region of the neck. It arises from the manubrium sterni and a median fibrous raphe. The fibers diverge dorso-cranially from this raphe to the sides of the neck, thinning out and blending into the superficial cervical fascia.⁵

Using a donkey (*Equus asinus*) cadaver instead of a horse cadaver for the surgical anatomy course at Texas A&M in 1982, I found this muscle to be more than a rudimentary layer. The muscle tissue on the donkey specimen was remarkably thicker, and it covered the middle one-third of the jugular furrow, in effect, obliterating the furrow in this region.⁶ The origin of the cutaneous colli was further up along the median raphe arising from the manubrium. Curiously, the manubrium of the donkey was also larger and protruded further forward. Notice the shape of the neck muscles and jugular furrow (Fig. 7).

Since that time, I have noticed that I can palpate that muscle on the live donkey. The jugular vein is more easily palpable above and below the muscle. To avoid the frustration of multiple attempts at venapuncture, the practitioner might use the upper one-

third or lower one-third of the jugular furrow to palpate the jugular vein before attempting the "stick."

Figure 8 shows the way this muscle tissue can frustrate the veterinarian's attempt to find the jugular vein. This cadaver of a miniature donkey foal has a dark bruised area where venapuncture was attempted. Notice that the jugular vein is deep to the cutaneous colli muscle (Fig. 9).

Nasolacrimal Duct

The rostral aperture of the naso-lacrimal duct of the donkey is located in a different area of the nostril flare than that of the horse. In the horse, the opening can be found at the muco-cutaneous junction on the floor of the nostril, slightly medially. In the donkey, the opening of the naso-lacrimal duct is located laterally on the flare of the nostril, and is slightly dorsal.⁶⁻⁸

The donkey is susceptible to fly-strike at the medial canthus of the eye. If the lacrimal duct and surrounding tissue becomes inflamed or infected, tears spill over and attract more flies. After addressing the removal of fly larva, infection or other sources of inflammation, the duct may still not be patent, deeming it necessary to irrigate the lacrimal duct from the nasal aperture.⁸

It is usually necessary to use a penlight and light sedation to locate this opening because of the very small size of the nostril of the donkey and his resentment of its handling (Fig. 10).

Sacrum and Coccygeal Vertebrae

The shape of the donkey sacrum and the spacing and direction of the spines of the sacrum and coccygeal



Fig. 9. Palpate the jugular vein in the upper one-third of the jugular furrow.

IN DEPTH: MULE/DONKEY MEDICINE AND SURGERY

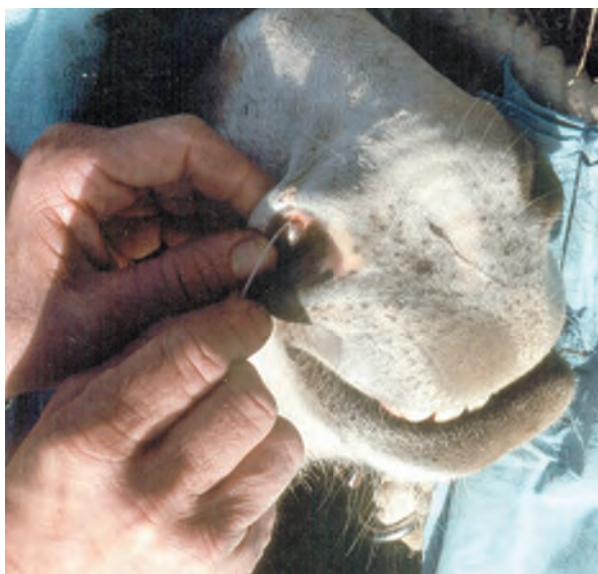

Fig. 10. The aperture of the nasolacrimal duct of the donkey is located on the flare of the nostril rather than on the floor of the nostril as it is in the horse.

vertebrae differ in the donkey.⁹ Also, the location of the end of the spinal cord and the end of the dura differs from those of the horse. Injection of a local anesthetic into the epidural region necessitates knowledge of these differences. Indications for caudal epidural anesthesia in the horse include surgical procedures involving the tail, perineum, anus, rectum, vulva, and vagina (as for Caslick's suture, rectovaginal tear repair, prolapsed rectum, or tail amputation), and symptomatic relief of pain during

obstetric manipulations.¹⁰ Most common indications for epidural anesthesia in the donkey include rectal or vaginal prolapse or to treat melanomas in the tail and perineal region.⁹

The sacrum of the horse is a relatively flat bone with five segments.¹¹ The donkey's sacrum also has five segments, but often the first coccygeal vertebra is fused to the sacrum with occlusion of the sacro-coccygeal space.¹² Further, the donkey sacrum is curved dorso-ventrally, directing the spinal canal ventrally in the caudal segments. The sacral spines point backwards and rapidly decrease in length caudally.⁹ The spinal canal slopes backward more steeply to end at the third coccygeal vertebra. The spinal cord ends at the second sacral vertebral segment, whereas the dural sheath extends back to the first or second coccygeal vertebra.¹³ The coccygeal vertebrae are much better developed in donkeys than in horses with the vertebral arches of the first three being complete and each having interarcuate ligaments. The first inter-coccygeal space in the donkey is narrower than the second space.⁹ In horses the spinal cord ends at the junction of the first and second sacral vertebral segments and the dural envelope at the fourth sacral segment.⁵ The vertebral arches of the second and third coccygeal vertebrae of horses are incomplete with the absence of any interarcuate ligaments.¹²

In the horse, anesthesia is injected in the first inter-coccygeal space at an angle of about 45° from the horizontal.¹¹ In the donkey, the injection site is in the second inter-coccygeal space, directing the needle at an angle of 30° from the horizontal. This site is more suitable because there is a wide interval between the second and third coccygeal vertebral

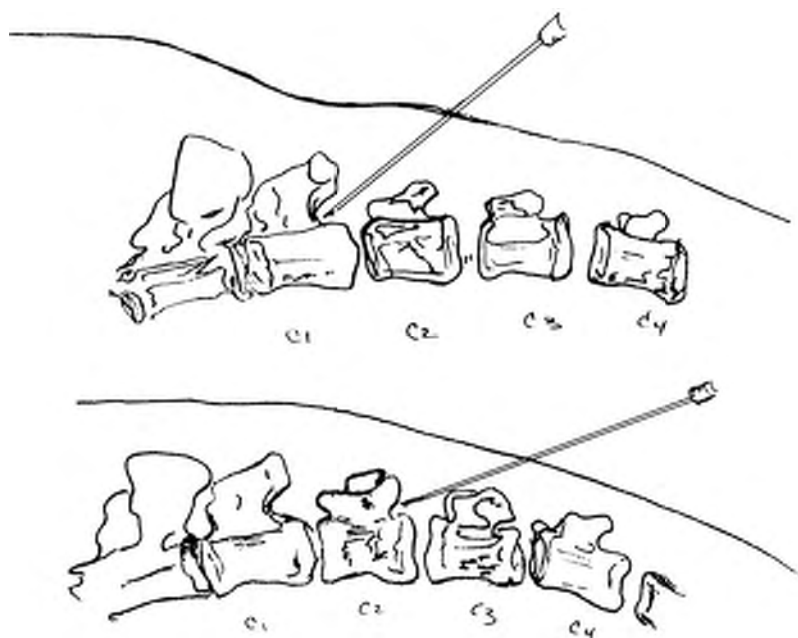


Fig. 11. The horse injection site between C1 and C2 (top). The donkey injection site between C2 and C3 (bottom).

IN DEPTH: MULE/DONKEY MEDICINE AND SURGERY

spines, and the anesthetic can be injected forward under the second coccygeal spine. The needle can be introduced into the vertebral canal here because there are no large tail muscles, and the spines of the sacral segments and the coccygeal spines are more easily palpated in the donkey.

By observing Figure 11 and noting the direction of the spines of the donkey sacrum, the veterinarian will note that the appropriate injection site will be one space further caudally than the site for the horse.

Vertebral Formula

The vertebral formula for the donkey is C₇, T₁₈, L₅, S₅, Ca₁₅₋₁₇.

The vertebral formula for the horse is C₇, T₁₈, L₆, S₅, Ca₁₅₋₂₁.¹⁴

Reproduction

The cervical anatomy of the female donkey (jenny) differs from that of the mare not only in size (being longer than the mare's and smaller in diameter) but also in the existence of a large protrusion from the cervix into the vagina. There are dorsal and ventral folds in the vaginal region that impede passage to the cervix, but they can be relaxed.¹⁵

A mare does not achieve the same degree of tone to her uterus when she is in foal to a jack.

6. Appendix 1

Hematology of Donkeys

The published studies of donkey hematology are limited. When compared with horse blood values, many of the studies indicated that donkey mean

Analyte	All Donkeys Mean (SD)
RBC (×10 ⁶ /l)	6.65 (1.05)
Hb (g/dl)	13.1 (1.7)
PCV (%)	38 (5)
MCV (fl)	57.9 (5.5)
MCHC (g/dl)	34.3 (1.1)
MCH (pg)	19.9 (1.9)
Platelets (×10 ³ /l)	330 (110)
WBC (×10 ³ /l)	10.3 (2.5)
Bands (%), (×10 ³ /l)	0.1 (0.3), 10 (20)
Neutrophils (%), (×10 ³ /l)	45.5 (11.5), 4.7 (1.7)
Lymphocytes (%), (×10 ³ /l)	42.9 (11.8), 4.4 (1.7)
Monocytes (%), (×10 ³ /l)	5.1 (2.9), 510 (290)
Eosinophils (%), (×10 ³ /l)	5.4 (4.4), 580 (530)
Basophils (%), (×10 ³ /l)	0.4 (0.5), 40 (50)
N:L ratio	1.3 (1.2)
Icteric index	2 (2)
Plasma protein (g/dl)	7.3 (0.6)
Fibrinogen (mg/dl)	300 (100)

From Zinkl JG, Mae D, et al. Reference ranges and influence of age and sex on hematologic and serum biochemical values in donkeys (*Equus asinus*). *Am J Vet Res* 51:3, 408-413.

levels were similar to the horse. The following are notable exceptions. The absence of reticulocytes in peripheral circulation was a common finding, even after severe hemorrhage.¹⁶⁻²⁰ Donkeys had fewer but larger erythrocytes.¹⁹ Greater values for mean corpuscular volume (MCV) were cited, averaging 55.6 (femtoliter)¹⁸ or 57.9 fl (femtoliter)¹⁹ compared with 44 fl (femtoliter)³³ for the horse. Serum lactate dehydrogenase (LD) activity was higher for the miniature donkeys than for other donkey breeds.¹⁹ All donkeys, obese miniature donkeys especially,²⁹ had higher plasma triglyceride levels.²¹ The icterus index and bilirubin concentration in donkeys were lower than values in horses.¹⁹ Serum creatine kinase and γ -glutamyltransferase activities in donkeys were higher than values for horses.¹⁹ Influences of age and sex on hematologic and serum biochemical values were noted but not consistently among the studies.

7. Appendix 2

Normal Temperature for the Donkey

The temperature of clinically normal donkeys ranges from 36-40°C, (96.8-104°F) with a diurnal variation.³⁴ The average rectal temperature is 37°C (98.6°F).³²

The donkey has diurnal variation.

Analyte	All Donkeys-Average Values Mean (SD)
Serum Protein (g/dl)	7.2 (0.7)
Albumin (g/dl)	3.3 (0.3)
Globulin (g/dl)	3.9 (0.7)
A:G	0.9 (0.2)
Total Bilirubin (mg/dl)	0.1 (0.2)
BUN (mg/dl)	18 (5)
Creatinine (mg/dl)	1.1 (0.3)
Glucose (mg/dl)	84 (22)
Cholesterol (mg/dl)	108 (30)
Creatine kinase CK (U/L)	64 (43)
Aspartate transaminase AST (U/L)	487 (119)
Alanine transaminase ALT (U/L)	18 (32)
L-itol (sorbitol) dehydrogenase ID (U/L)	3 (1)
Alkaline phosphatase ALP (U/L)	236 (75)
G-glutamyl transferase GGT (U/L)	69 (29)
Lactate dehydrogenase LD (U/L)	427 (161) **600 (194) for miniatures
Inorganic Phosphorus IP (mg/dl)	4.3 (1.3)
Ca (mg/dl)	11.8 (0.8)
Mg (mg/dl)	2.6 (0.4)
Na (mEq/L)	141 (4)
K (mEq/L)	4.2 (0.6)
Cl (mEq/L)	102 (3)

From Zinkl et al. Reference ranges and the influence of age and sex on hematologic and serum biochemical values in donkeys (*Equus asinus*). *Am J Vet Res* 51:3, 408-413.

IN DEPTH: MULE/DONKEY MEDICINE AND SURGERY

- Minimum body temperature in cool early morning hours as low as 35.5°C, (95.9°F)
- Maximum body temperature is 39.0°C (102.2°F) and is reached at noon for ambient temperature ranges of 16–40°C (60–104°F)
- When exposed to 46.0°C (115°F) ambient temperature, the body temperature did not rise above 39.2°C (102.2°F)³⁴
- The highest observed temperature was 39.5°C (103.1°F) for animals that were dehydrated for 36 h and then taken for a 12-h walk in the desert at the rate of 70–80 m/min. Under this severe condition, the donkey seemingly had no difficulty in keeping cool and preventing any explosive rise in rectal temperature.³⁴
- Hypothermia in donkeys was defined as having rectal temperature below 35°C (95°F). Hypothermia is a problem in donkeys during cold winter months and may not be secondary to other disease or related to diet or management.³²

References

1. Manly Miles MD. *Principles of Stock Breeding*. New York: D. Appleton & Co., 1879.
2. Lindsay EF, Clayton HM. An anatomical and endoscopic study of the nasopharynx and larynx of the donkey (*Equus asinus*). *J Anat* 1986;144:123–132.
3. Fores P, Lopez J, Rodriguez A, et al. Endoscopy of the upper airways and the proximal digestive tract in the donkey (*Equus asinus*). *J Equine Vet Sci* 2001;21:17–20.
4. Hutchins B. The donkey in veterinary practice. *Equine Pract* 1984;6:8–12.
5. Sack WO, Habel RE. *Rooney's Guide to the Dissection of the Horse*. 3rd ed. Ithaca, NY: Veterinary Textbooks, 1977.
6. Schoener, S. *The Definitive Donkey*, 1st ed. Gainsville, TX: Gainsville Printing Co., 1981, pp. 216–221.
7. Said AH, Shokry M, Saleh MA, et al. Contribution to the nasolacrimal duct of donkeys in Egypt. *Anatomia Histologia Embryologia* 1977;6:347–350.
8. Pohlmeier K, Wissdorf H. Anatomic basis for irrigation of the lacrimal ducts of donkeys (*Equus africanus f. asinus*—Macedonian dwarf donkey). *Deutsche Tierärztliche Wochenschrift* 1975;82:314–316.
9. Shoukry M, Saleh M, Fouad K. Epidural anesthesia in donkeys. *Vet Rec* 1975;97:450–452.
10. Mansmann RA, McAllister ES. *Equine Medicine and Surgery*. Santa Barbara, CA: American Veterinary Publications, 1982, p. 244.
11. Heath EH, Myers VS. Topographic anatomy for caudal anesthesia in the horse. *Vet Med* 1972;67:1237.
12. Sisson S. *Anatomy of the Domestic Animals*. Philadelphia, PA: W. B. Saunders, 1948.
13. Naeini AT, Rezakhani A, Ahmmadian M. Comparison of morphine, fentanyl, methadone, lidocaine and lidocaine/epinephrine as a caudal epidural analgesics in donkeys. *J Appl Anim Res* 1999;15:181–184.
14. Jamdar MN, Ema AN. A note on the vertebral formula of the donkey. *Br Vet J* 1982;138:209–211.
15. Vendramini OM, Guintard C, Moreau J, et al. Cervix conformation: a first anatomical approach in Baudet du Poitou asses. *Br Soc Anim Sci* 1998;66:741–744.
16. Wilding JL, Kimball AW, Whitaker MW, et al. Some blood values of the southwestern burro (*Equus asinus asinus*). *Am J Vet Res* 1952;13:509–513.
17. Nayeri GD. Blood characteristics of the adult donkey. *Zentralbl Vet Med A* 1978;25:541–547.
18. Brown Daniel G, Cross Fannie H. Hematologic values of burros from birth to maturity: cellular elements of peripheral blood. *Am J Vet Res* 1969;30:1921–1927.
19. Zinkl JG, Doni M, Pedro GM, et al. Reference ranges and the influence of age and sex on hematologic and serum biochemical values in donkeys (*Equus asinus*). *Am J Vet Res* 1990;51:408–413.
20. Gupta AK, Varshney JP, Ghei JC, et al. Some haematobiochemical studies in Indian donkeys, (*Equus asinus*). *Indian Vet J* 1992;69:21–24.
21. Straub R, Gerber H, Petitjean J. Serum-lipids in horses, ponies, donkeys, and mules, in *Proceedings*. 1st Int Symp Equine Hematol 1977;228–236.
22. French JM, Patrick VH. Reference values for physiological, haematological and biochemical parameters in domestic donkeys (*Equus asinus*). *Equine Vet Edu* 1995;7:33–35.
23. Yousef MK, Dill DB, Morris JD Jr. Red blood cell and plasma volumes in the burro, *Equus asinus*: desert and mountain. *J Appl Physiol* 1971;31:253–256.
24. Engel RE, Cartwright S, Spurell FA. Classification of circulating leucocytes in the normal Mexican burro. *Am J Vet Res* 1964;27:1478–1484.
25. Folch P, Jordana JJ, Cuenca R. Reference ranges and the influence of age and sex on haematological values of the endangered Catalanian donkey. *Equine Vet J* 1997;154:163–168.
26. Jordana J, Folch P, Cuenca R. Clinical biochemical parameters of the endangered Catalanian donkey breed: normal values and the influence of sex, age, and management practices effect. *Res Vet Sci* 1998;64:7–10.
27. Yousef MK. The burro: a new backyard pet? Its physiology and survival. *Calif Vet* 1979;33:31–34.
28. Yousef MK, Davis TP, Johnson HD. Partition of body fluids in the burro. *J Wildlife Manage* 1978;42:923–925.
29. Watson TDG, Packard CJ, Shepherd J, et al. An investigation of the relationships between body condition and plasma lipid and lipoprotein concentrations in 24 donkeys. *Vet Rec* 1990;127:498–500.
30. Forhead AJ, French J, Ikin P, et al. Relationship between plasma insulin and triglyceride concentrations in hypertriglyceridaemic donkeys. *Res Vet Sci* 1994;56:389–392.
31. El-Nouty FD, Yousef MK, Magdub AB, et al. Thyroid hormones and metabolic rate in burros, *Equus Asinus*, and Llamas, *Lama glama*: effects of environmental temperature. *Comp Biochem Physiol* 1978;60A:235–237.
32. Stephen JO, Baptiste KE, Townsend HGG. Clinical and pathological findings in donkeys with hypothermia: 10 cases (1988–1998). *J Am Vet Med Assoc* 2000;216:725–729.
33. Krehbiel JD. *Current Therapy In Equine Medicine*. Philadelphia, PA: WB Saunders Co., 1983;619.
34. Yousef MK. The burro: a new backyard pet? *Calif Vet* 33:31–34.

References 22–28, 30, and 31 support the graphs in Appendix 1 and 2.

Suggested Reading

- Tegetmeyer, Sutherland. *Horses, Asses, Zebras, and Mules*. London: Horace Cox. "Field Office" Windsor House, 1895.
- Anderson WS, Hooper JJ. *American Jack Stock and Mule Production*. Bulletin no. 212. KY: Kentucky Agricultural Experiment Station, Lexington: University of Kentucky, Bulletin No. 212.
- Williams JO. *Mule Production*. Bulletin no. 1341. U.S. Department of Agriculture, Washington, DC, 1923.
- Short RV. The contribution of the mule to scientific thought. *J Reprod Fertil* 1975;Suppl 23:359–364.
- Savory TH. The mule. *Sci Am* WH Freeman & Co, San Francisco 1970;223:102–109.
- Brookshier F. *The Burro*. Norman, OK: University of Oklahoma Press, 1974.